AU17: page 100	Pls. check dosage ✔

tit0100

MANAGEMENT OF LOWER GASTROINTESTINAL BLEEDING

Anna Liveris, MD and Peter ~~Muscarellall,~~ MD

st1540

INTRODUCTION

p3625 Lower gastrointestinal bleeding (LGIB) is a frequently encountered and complex clinical problem for surgeons. Classically defined as gastrointestinal (GI) bleeding emanating from any point distal to the ligament of Treitz, LGIB can originate anywhere from the small bowel to the anus and accounts for an estimated 30% of all GI bleeding. Nearly all LGIB can be isolated to the colon and rectum, with diverticular bleeding being the most common cause. Less than 10% of LGIB originates from the small bowel or anus. Aggressive resuscitation, accurate localization, and control of bleeding are the primary goals of treatment for patients who present with hemorrhagic shock. A systematic approach to diagnosis and management is pivotal in reducing morbidity and mortality.

st1545

Etiology

p3630 LGIB can be further categorized as massive, moderate, or occult. Massive bleeds are the most life-threatening, with mortality rates approaching 20%. Despite this, more than 80% of all LGIB will resolve spontaneously, and the overall mortality rate is about 4%. Patients presenting with massive LGIB are usually >65 years and present with hematochezia or bright red blood per rectum in the setting of hemodynamic instability. The most common causes are diverticulosis and angiodysplasia. Interestingly, one-third of patients with presumed massive LGIB will have an upper GI source, so assessing for risk factors of peptic ulcer disease is important.

p3635 Moderate and occult bleeding can occur at any age. Moderate LGIB presents as hematochezia or melena in a hemodynamically stable patient. The differential diagnosis is broad (Table 1). Occult LGIB is otherwise asymptomatic, except for microcytic anemia resulting from chronic blood loss. The differential diagnosis of these patients includes malignancy, inflammatory conditions, ischemia, and congenital causes such as bleeding Meckel's diverticula.

st1550

Epidemiology

p3640 Approximately 30% of all patients presenting with major GI bleeding are found to have bleeding distal to the ligament of Treitz. Among patients with presumed LGIB, 80% originate distal to the ileocecal valve, with only 10% originating from the small bowel. The remaining cases usually arise in the upper GI tract. The overall incidence of LGIB is notably higher in older adult patients, particularly those who are on multiple medications.

p3645 Diverticulosis accounts for over 40% cases of LGIB and often presents as painless hematochezia. Diverticular bleeding frequently recurs, and the prevalence increases in patients older than 80 years of age or in those with chronic constipation. Ischemic colitis accounts for 20% of LGIB and is also more prevalent in the elderly. This may occur in response to reduced mesenteric flow to the colon caused by decreased cardiac output, vasospasm, or atherosclerotic disease. Treatment is generally supportive and conservative unless there is evidence of full-thickness necrosis and/or peritonitis. The watershed area of the splenic flexure is a common location for ischemic colitis, and involvement of this area on imaging should alert the clinician to the possibility of this diagnosis. The most common cause of LGIB in patients younger than 50 years of age is benign anorectal disease, usually hemorrhoids or anal fissures. The possibility of inflammatory bowel disease (IBD) or NSAID-induced mucosal ulceration should also be considered in these patients. Post-polypectomy bleeding can result in brisk bleeding following colonoscopy and polypectomy. Risk factors include age greater than 65 years and polyp size larger than 1 cm. Though the bleeding is usually self-limited, presentation can be delayed for up to 1 week after the procedure; therefore ascertaining the history of colonoscopy with polypectomy is crucial.

t0115

TABLE 1 Differential Diagnosis of Lower Gastrointestinal Bleeding

Anatomic Source of Bleeding	Etiologies
Small intestine	Angiodysplasia Crohn's disease Mesenteric ischemia Recent surgery/trauma Meckel's diverticulum Dieulafoy's lesion Aortoenteric fistula Intussusception
Colon	Diverticulosis Neoplasm Angiodysplasia Inflammatory bowel disease Recent colorectal surgery/trauma Recent colonoscopy/polypectomyIschemic colitis Infectious colitis Enterohemorrhagic *Escherichia coli* (EHEC) *Salmonella* *Campylobacter* *Shigella* *Cytomegalovirus* *Entamoeba histolytica* Fecal impaction Aortoenteric fistula
Rectum	Radiation proctitis Neoplasm Angiodysplasia Rectal varices Fecal impaction Inflammatory bowel disease Solitary rectal ulcer Rectal prolapse Recent colorectal surgery/trauma
Anus	Hemorrhoids Anal fissure Inflammatory bowel disease Local trauma Perianal variceal disease

st1555

History and Physical Examination

p3650 The differential diagnosis for LGIB is broad, so a thorough history and physical examination is necessary. The history may suggest a cause of LGIB and can inform decision making regarding

diagnostic evaluation and management. Key details in the history should include the quantity, quality, and frequency of the bleeding, specifically whether the bleeding is recurrent or sporadic. Inquiry into other associated symptoms such as presence of abdominal pain, nausea, vomiting, or a recent change in bowel habits is also warranted. The clinician should specifically inquire about prior episodes of LGIB, history of abdominopelvic radiation, trauma, symptomatic arrhythmias, liver disease or cirrhosis, HIV status, and recent endoscopic or surgical procedures. A detailed review of the patient's medications including antiplatelet agents, anticoagulants, and NSAIDs as well as a family history of colon cancer or inflammatory bowel disease should also be noted.

p3655 Abdominal examination and digital rectal examination should be completed in all patients presenting with LGIB. Abdominal examination may reveal tenderness, distension, or a mass. Digital rectal examination is important to inspect for anorectal pathology such as hemorrhoids or fissures. Additionally, the quality of the stool in the rectal vault, whether it is impacted, dark melena, maroon-colored, or frank blood, should be documented. Importantly, the clinician should pay close attention to the patient's vital signs at all points during the history and physical examination as any hemodynamic instability warrants a rapid resuscitation and aggressive diagnostic effort.

st1560

MANAGEMENT

p3660 All patients presenting with LGIB should be triaged and evaluated immediately as decompensation can be rapid. Administration of supplemental oxygen, the establishment of intravenous lines access with two large-bore peripheral venous catheters, and placement on a cardiopulmonary monitor should be performed initially. Infusion of crystalloid solutions should be started immediately to resuscitate the patient. Laboratory examination should include a complete blood count, metabolic panel, liver function tests, lactate, coagulation studies, and a type and screen.

st1565

Resuscitation and Transfusion

p3665 Appropriate resuscitation of a patient with LGIB is crucial to minimize morbidity. The process should begin as described earlier as soon as it is recognized that the patient is actively bleeding. For patients with evidence of multiple comorbidities or massive LGIB, a critical care consultation and monitoring in a critical care setting is warranted.

p3670 Most patients with moderate or occult LGIB present without signs of instability. These patients may warrant less aggressive resuscitation with crystalloid during their initial workup and evaluation. Transfusion should be initiated to correct any overt coagulopathy and to maintain a hemoglobin >7 g/dL for most patients. Some patients, particularly those with other comorbidities, may require a higher goal hemoglobin and should be treated on an individual basis. International normalized ratio (INR) should be corrected to <1.5, and platelets should be transfused to >50,000/μL.

p3675 The massive LGIB patient who presents in hemorrhagic shock is similar to a trauma patient. Therefore, activation of a massive transfusion protocol and the use of empiric blood product ratios of 1:1:1 of packed red blood cells to fresh-frozen plasma to platelets in order to correct coagulopathy is effective. Early use of fresh-frozen plasma and platelets should be considered. The end goals of resuscitation are correction of coagulopathy and hemodynamic support. A policy of permissive hypotension with systolic blood pressure >90 mm Hg is sufficient for most patients. Although crystalloid solutions may be indicated in other cases of LGIB, care should be taken to avoid the overuse of crystalloids in this subset of patients because this may contribute to bowel edema and other complications such as abdominal compartment syndrome or respiratory failure. The use of thromboelastography (TEG) may also be a useful adjunct for the care of the hemodynamically unstable LGIB patient in centers where this technology is available. Prompt progression to the next phases of management, bleeding localization and hemorrhagic control, is important to minimize mortality. Aggressive efforts to correct coagulopathy and metabolic derangements before surgical intervention should be undertaken, although salvage procedures may be required in rare cases. This will be discussed further in later sections.

st1570

Special Hematologic Considerations

p3680 Early identification of hematologic disorders or medications is mandatory during the resuscitative process. Laboratory studies, including traditional coagulation studies and possibly TEG, should be obtained during the initial workup. Anticoagulants and antiplatelet agents should be discontinued, and reversal should be considered in patients with hemodynamic instability or ongoing bleeding. For patients who are therapeutic or supratherapeutic on warfarin, a prothrombin concentrate complex should be considered. Vitamin K and fresh-frozen plasma can also be utilized for this purpose, but prothrombin complex concentrate has the advantage of rapid reversal with lower fluid volumes. In recent years, idarucizumab has become more readily available to reverse dabigatran. Although not widely available yet, andexanet alfa has also been approved by the US Food and Drug Administration (FDA) for the reversal of apixaban and rivaroxaban. Currently, there is no specific reversal agent for antiplatelet agents such as aspirin and clopidogrel. Most clinicians favor early platelet transfusion and/or desmopressin administration in the setting of active hemorrhage. Cardiology consultation should be considered for patients who have had drug-eluting cardiac stents placed within the past year because they are at risk for stent thrombosis if dual antiplatelet agents are discontinued, and this can contribute to mortality. It may be reasonable to continue aspirin therapy in some of these patients. Desmopressin administration can be particularly useful to reverse coagulopathy in the uremic patient. For patients with inherited or acquired coagulation disorders, specific reversal agents and therapies should be guided in consultation with the hematology service. More specialized laboratory studies may be indicated in some patients.

st1575

Localization

p3685 The first step in management and hemorrhage control is localization of the bleeding site. As previously discussed, LGIB has a broad differential, and identifying the source of bleeding is tantamount to further management.

st1580

Nasogastric Lavage

p3690 An upper GI source should always be considered in patients with suspected LGIB, particularly in patients with hemodynamic instability, brisk bleeding, or unrevealing evaluation of the lower GI tract. Bleeding peptic ulcers, angiodysplasia, or esophageal varices can often manifest as visible blood in the stool. Clearly, management diverges drastically if the source of bleeding is in the upper GI tract. Nasogastric lavage has classically been recommended as the first step in determining an upper versus lower GI source, particularly in the unstable patient. A nasogastric tube is inserted bedside, and then the contents of the stomach are suctioned. Alternatively, 200 to 300 mL saline is instilled into the tube and then suctioned back to look for blood or coffee grounds in the stomach. Fluid with bile present but without blood is considered to be a negative lavage. The lack of bilious fluid suggests inadequate evaluation of the post-pyloric region. A clear effluent is considered nondiagnostic and is not uncommon. Disadvantages of nasogastric lavage include patient discomfort and lack of therapeutic benefit. Nasogastric lavage has fallen out of favor in recent years and should be reserved for cases of suspected upper GI hemorrhage to improve visualization at the time of endoscopy. The authors liberally employ the use of upper endoscopy for the evaluation and management of GI bleeding because of its numerous advantages.

st1585

Anoscopy/Rigid Sigmoidoscopy

p3695 In patients with a strong suspicion for GI bleeding from the anorectum or distal sigmoid, anoscopy or rigid sigmoidoscopy should

be considered. Anoscopy can be quickly performed with little to no sedation at the bedside by inserting a tubular instrument into the patient's anus to visualize hemorrhoids, anal fissures, fecal impaction, or local trauma to the anus. Anoscopy can also be therapeutic as it can be used to assist with banding or other treatment of bleeding hemorrhoids. Rigid sigmoidoscopy is also a technically simple bedside procedure but generally requires additional sedation. The instrument is longer and allows for insufflation, which can facilitate visualization of the rectal and distal sigmoid mucosa. Both procedures can be uncomfortable for the patient and provide limited visualization of the most distal GI tract. When possible, flexible sigmoidoscopy or colonoscopy is preferred.

st1590 ### *Colonoscopy*

p3700 When there is a high degree of suspicion for a colorectal source of LGIB, colonoscopy is the modality of choice to localize the source if possible. It has been shown to correctly identify the location of LGIB in more than 75% of patients. Colonoscopy is performed using a flexible scope guided from the anus through the entirety of the rectum and colon until the ileocecal valve is reached. Colonoscopy can detect discrete sources of bleeding, such diverticula, angiodysplasia, and tumors, as well as more diffuse sources of bleeding, such as inflammatory bowel disease, ischemic colitis, and radiation proctitis.

An important benefit of the procedure is the ability to perform p3705 therapeutic intervention. Bleeding should only be ascribed to lesions with stigmata of recent hemorrhage, including visualized bleeding, exposed blood vessels, or adherent clots. Colonoscopic hemostasis can be achieved with dilute epinephrine injections (1:10,000 or 1:20,000) in 1 to 2 mL aliquots. This result is usually temporary, and a second [AU17] hemostatic method is recommended. Epinephrine injections are best suited to facilitate site identification in cases of active or copious bleeding. Endoclip placement results in hemostasis for nearly all diverticular bleeds with stigmata of recent hemorrhage and in nearly 70% with other forms of LGIB (Fig. 1). Other endoscopic techniques for hemostasis include bipolar electrocoagulation, heater probe cautery, argon plasma coagulation, and rubber band ligation. Angiodysplasia is particularly amenable to argon plasma coagulation (Fig. 2). Rubber band ligation has the highest rates of rebleeding and can add significant procedure time depending on the site. Tattooing is recommended to expedite site identification in the event of recurrent bleeding, particularly if surgical intervention is determined to be necessary.

The timing of colonoscopy in the evaluation of LGIB remains p3710 controversial. Ideally, a bowel prep should be attempted to maximize visualization during the procedure. Notably, early colonoscopy performed while the patient is actively bleeding has been shown to improve diagnostic yield. Colonoscopic evaluation following bowel

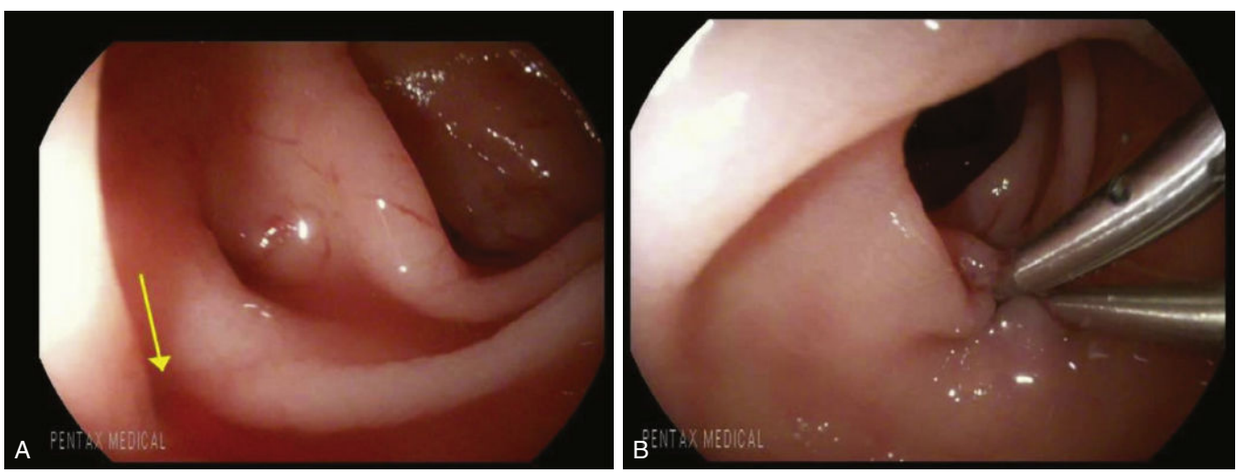

f0360 **FIG. 1** **(A)** Colonic diverticulum with stigmata of recent hemorrhage. **(B)** Successful endoscopic clipping of bleeding diverticulum. *(Courtesy Daniel S. Behin, MD, Montefiore Medical Center/Albert Einstein College of Medicine, New York.)*

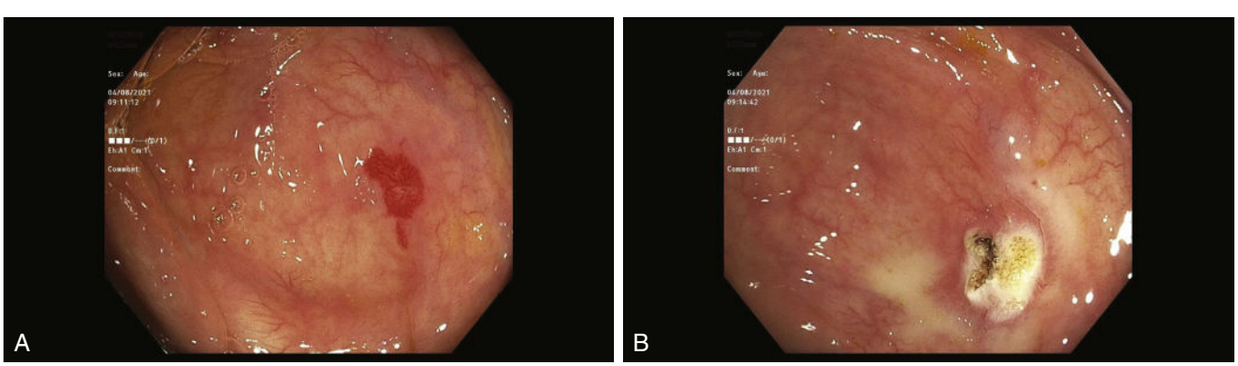

f0365 **FIG. 2** Cecal angiodysplasia before **(A)** and after **(B)** endoscopic argon beam plasma coagulation. *(Courtesy Daniel S. Behin, MD, Montefiore Medical Center/Albert Einstein College of Medicine, New York.)*

preparation is generally recommended within the first 24 hours of admission for patients with LGIB.

p3715 If the patient is not stable enough for endoscopic evaluation, radiologic evaluation or surgical intervention should be considered as an alternative. Colonoscopy should also be deferred if there is suspicion for active diverticulitis as this reportedly increases the risk of perforation. Other procedural risks include mucosal injury and the general risks of anesthesia/sedation.

st1595

Computed Tomographic Angiography

p3720 Computed tomographic angiography (CTA) is an important diagnostic tool for the evaluation of active LGIB. The study is performed using intravenous contrast timed such that active arterial extravasation from a vessel into the lumen of the small bowel can be visualized on a multidetector helical CT scanner. Extravasation of intravenous contrast into the lumen of the bowel, or an active "blush," constitutes a positive finding (Fig. 3). This study has a sensitivity close to 90% and can detect bleeding rates as low as 0.3 mL/min to 0.5 mL/min. Localization accuracy is as high as 97% in patients with high transfusion requirements and/or hemodynamic instability. Unfortunately, CTA has a relatively low specificity of 85%.

p3725 CTA is widely available, fast, minimally invasive, and does not require any bowel preparation or oral contrast administration. As a result, it is very useful in hemodynamically unstable patients who do not have time to undergo bowel preparation before intervention and are transiently responding to resuscitation. CTA is also useful in identifying other causes of LGIB such as ischemic colitis and can be used to evaluate the small bowel. Disadvantages include the requisite for active hemorrhage at the time of the study, possible allergic reaction to intravenous contrast, radiation exposure, difficulty with precise localization of a small-intestinal source, and lack of direct therapeutic application.

st1600

Nuclear Scintigraphy with Technetium-99m

p3730 Like CTA, nuclear scintigraphy allows for radiographic location of LGIB and is purely a diagnostic test. The patient's red blood cells are tagged with the radiotracer Technetium-99m (^{99m}Tc) and re-injected into the patient followed by sequential imaging. Nuclear scintigraphy is a far more sensitive test than CTA as it can detect bleeding rates as low as 0.1 mL/min. An important advantage of this study is its ability to detect bleeding occurring up to 24 hours after tracer injection as the radiolabeled red blood cells remain detectable. The half-life of ^{99m}Tc allows for sequential imaging several times in a 24-hour period.

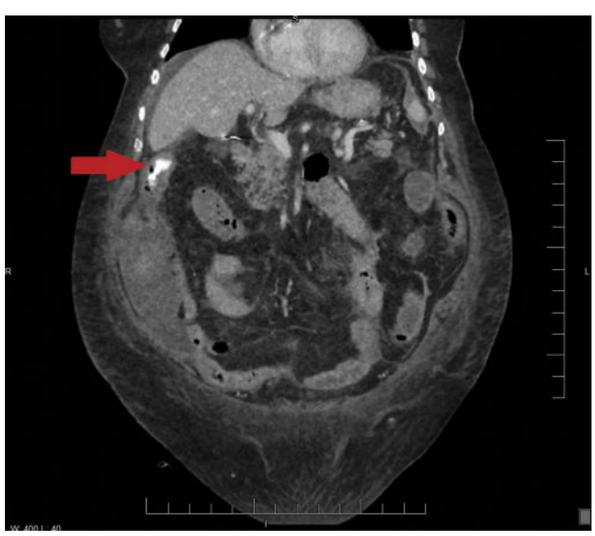

f0370 **FIG. 3** Active extravasation of contrast in the hepatic flexure of a patient with lower gastrointestinal bleeding identified by CTA. *(Courtesy Michael F Petroziello, MD, Roswell Park Cancer Institute Hospital, Buffalo, NY.)*

Despite the high sensitivity rates, nuclear scintigraphy results in p3735 false localization rates approaching 25% have been reported, making it less accurate than CTA. This study is best suited as a screening tool for hemodynamically stable patients with scant, intermittent bleeding and not for definitive localization. Arteriography is generally warranted in the event of a positive study for localization and possible therapeutic intervention. Surgical intervention, particularly segmental resection, should not be guided by the results of nuclear scintigraphy.

st1605

Angiography

Angiography offers the advantages of accurate localization and the p3740 opportunity for therapeutic intervention, and it is a particularly useful option in patients with unstable vital signs requiring ongoing blood transfusions. Appropriate indications include copious bleeding precluding colonoscopic evaluation and positive extravasation on CTA or nuclear scintigraphy. For the latter, angiography further localizes the source of bleeding and potentially allows for hemorrhage control. These patients require little to no sedation, and access is usually obtained through the femoral artery. Fluoroscopic visualization is used to identify extravasation following selective mesenteric arterial cannulation and injection of contrast material. Angiography can detect bleeding at rates as low as 0.5 mL/min and has a high sensitivity for LGIB. Overall, it is a better test for patients with profuse, active bleeding than for those with scant, intermittent bleeding.

Embolization can be attempted for patients with positive localiza- p3745 tion during angiography. Super subselection with microcatheters and microcoil embolization are preferred when possible. Embolization, including highly selective embolization, is clinically successful in the majority of cases, with demonstrated bleeding resolution rates of 75% to 90%, depending on the location (Fig. 4). Other therapeutic options include intraarterial infusion with vasopressin, a potent vasoconstrictor, which is effective in substantially decreasing bleeding. These maneuvers may eliminate the need for emergent operation and facilitate continued resuscitation followed by surgical intervention under more controlled circumstances. For cases of venous bleeding, embolization of the venous system is possible, though not frequently undertaken.

Many have advocated for the preferential use of angiography in p3750 frail patients with severe comorbidities for whom an emergent operation would carry a prohibitively high mortality. Angiography is usually reserved for hemodynamically unstable patients or patients with a continued transfusion requirement. Unfortunately, the rebleeding rate is not insignificant and approaches 20% in some studies. Potential risks of angiography include bowel ischemia, contrast allergy or nephropathy, the risks of sedation, pseudoaneurysm, hematoma, and other vascular complications at the access site. Table 2 outlines and compares salient characteristic features of the various radiologic diagnostic and treatment options.

For patients with intermittent, obscure LGIB that has not been p3755 identified via other methods, provocative angiography is a technique that can be utilized. During this procedure, a therapeutic dose of anticoagulant is administered with the goal of provoking the bleeding lesion into an active hemorrhage so it can be captured on angiography. The lesion is then embolized in the same fashion as described previously. Systemic anticoagulation is usually achieved with heparin and followed by incremental and selective transcatheter injection of urokinase and a vasodilator, such as nicardipine. Multiple studies have shown that this procedure has an acceptable risk profile, including minimal risk of bleeding complications from the anticoagulant.

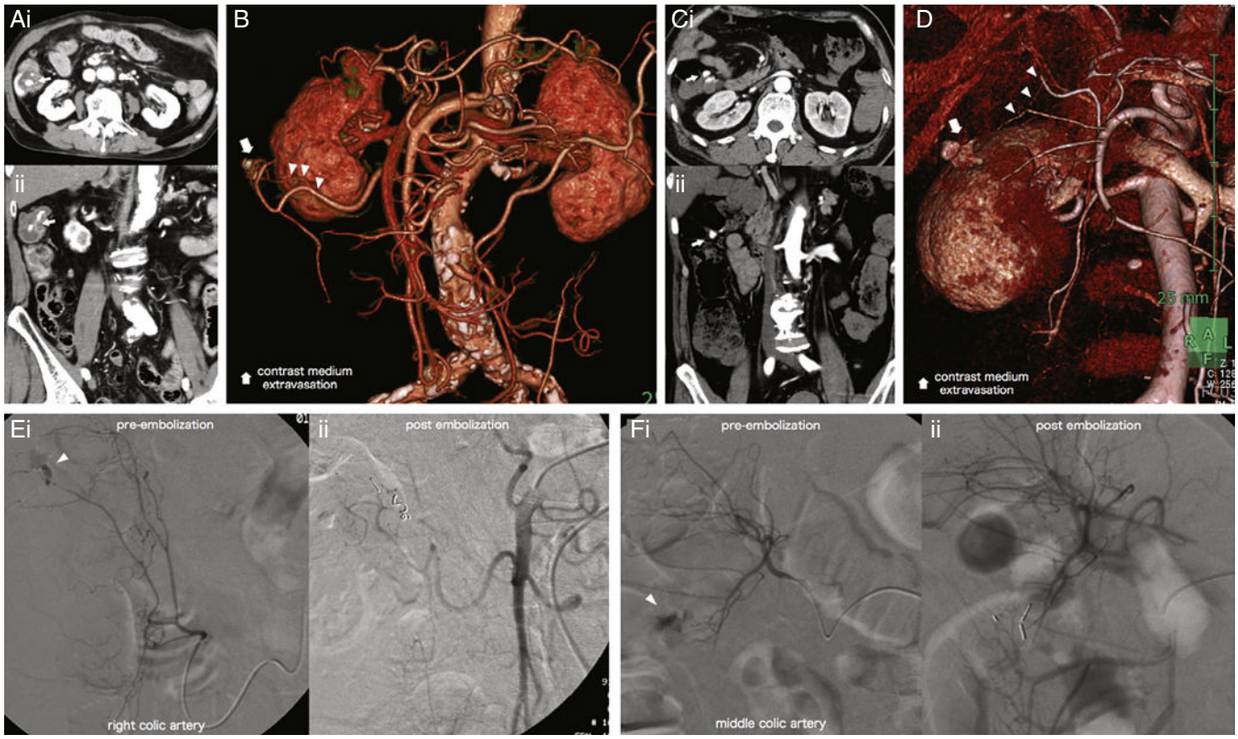

f0375 **FIG. 4** Bleeding at the hepatic flexure of the colon secondary to diverticulosis in two patients. Multiplanar reconstruction (MPR) and volume-rendered 3D reconstruction of arterial-phase CT images reveal arterial bleeding from the peripheral branch of the right colic artery **(A** and **B)** and the middle colic artery **(C** and **D).** Pre- and postembolization images demonstrate extravasation of contrast from the involved vessels and resolution of bleeding, respectively **(E** and **F).** *(From Tsurukiri J, Ueno M, Kaneko N. Bleeding at the hepatic flexure of the colon secondary to diverticulosis.* Clin Gastroenterol Hepatol. *2012;10:e11–e12.)*

t0120 **TABLE 2 Radiologic Imaging Tests for Evaluation of Lower Gastrointestinal Bleeding with Their Associated Characteristics**

Study	Invasive Procedure	Bleeding Detection Rate (mL/min)	Capacity for	
			Localization	Intervention
CTA	–	0.3–0.5	+	–
NS	–	0.1	–	–
Angiography	+	0.5	+	+

CTA, Computed tomographic angiography; *NS,* nuclear scintigraphy.

Nearly one-third of patients with a previous unidentified source of LGIB have a source identified with provocative angiography. Bleeding lesions can be treated by embolization or surgical resection. Resection is the preferred treatment for hypervascular neoplasms and can be useful for selected patients with angiodysplasia. If surgical resection is being considered and no mass lesion is identified at the time of selective arteriography, a microcatheter should be left in the feeding artery. The patient should be brought to the operating room in an expeditious fashion for surgical exploration. Injection of the catheter with blue dye will allow for visualization of the involved segment and can be used to guide the extent of resection.

st1610 ### *Capsule Endoscopy*

p3760 Although the majority of LGIB is colonic in origin, some cases of obscure bleeding originate from the small bowel. Capsule endoscopy is a useful modality for the subset of patients who have persistent bleeding and negative endoscopic evaluations of the colon and foregut. The patient swallows a pill-sized capsule that contains a small camera. The camera takes intermittent photographs as it travels through the patient's GI tract, and the photos are retrieved after the capsule is returned. The images are reviewed carefully to determine the source of bleeding. Capsule endoscopy is therefore best suited for hemodynamically normal patients who have chronic GI bleeding with a suspected small intestinal source. Diagnostic accuracy is good with sensitivities and specificities of approximately 90% and 95%, respectively. Diagnostic yield is improved in patients with acute bleeding and in those taking anticoagulants. The procedure is noninvasive and has an overall low complication rate; however, complications may include battery failure, capsule retention, and bowel perforation. Other disadvantages include the lack of potential for localization or therapeutic intervention. Patients may be administered a test capsule made of absorbable material before the

actual pill camera if the patient is at high risk for a retained capsule. Surgical intervention is required for retained capsules but may result in accurate identification and treatment of the bleeding pathology in rare circumstances.

st1615

Double Balloon Enteroscopy

p3765

Similar to capsule endoscopy, double balloon enteroscopy allows for visualization of the small bowel. The study is performed under anesthesia/sedation. An endoscope is utilized with the addition of an overtube. Both the endoscope and overtube have balloons at their distal aspects. The procedure begins like any other endoscopy, and the endoscope is advanced into the proximal small bowel. The overtube balloon is then inflated and the overtube retracted, thus pulling the small bowel toward the endoscope and allowing the latter to advance further into the small bowel. To pass further, the endoscope's balloon is inflated, and the overtube's balloon deflated advancing it forward to meet the endoscope. This tedious process allows the endoscope to advance though the small bowel as a result of retraction of the overtube.

Frequently, patients have already undergone CTA or capsule endoscopy to identify an area of interest. The major advantages over capsule endoscopy include the potential for therapeutic intervention and tissue sampling. In addition, double balloon endoscopy can be performed via the transoral or transanal routes. Disadvantages include the risk of bowel perforation and the risks associated with anesthesia as well as prolonged duration of the procedures, often lasting 60 to 90 minutes. p3770

Management Algorithm for LGIB

st1620

Further management of the patient presenting with LGIB depends on the results of the aforementioned localization studies. A treatment algorithm is proposed to guide management for these complex patients (Fig. 5). We recommend colonoscopy as a first-line test for stable patients with mild or moderate LGIB. Many of these patients will have diverticular bleeding, and this has been shown to resolve spontaneously in 80% of cases, with most patients receiving fewer than 4 units of blood. This is irrespective of colonoscopic intervention. Up to one-third of spontaneously resolving diverticular bleeds p3775

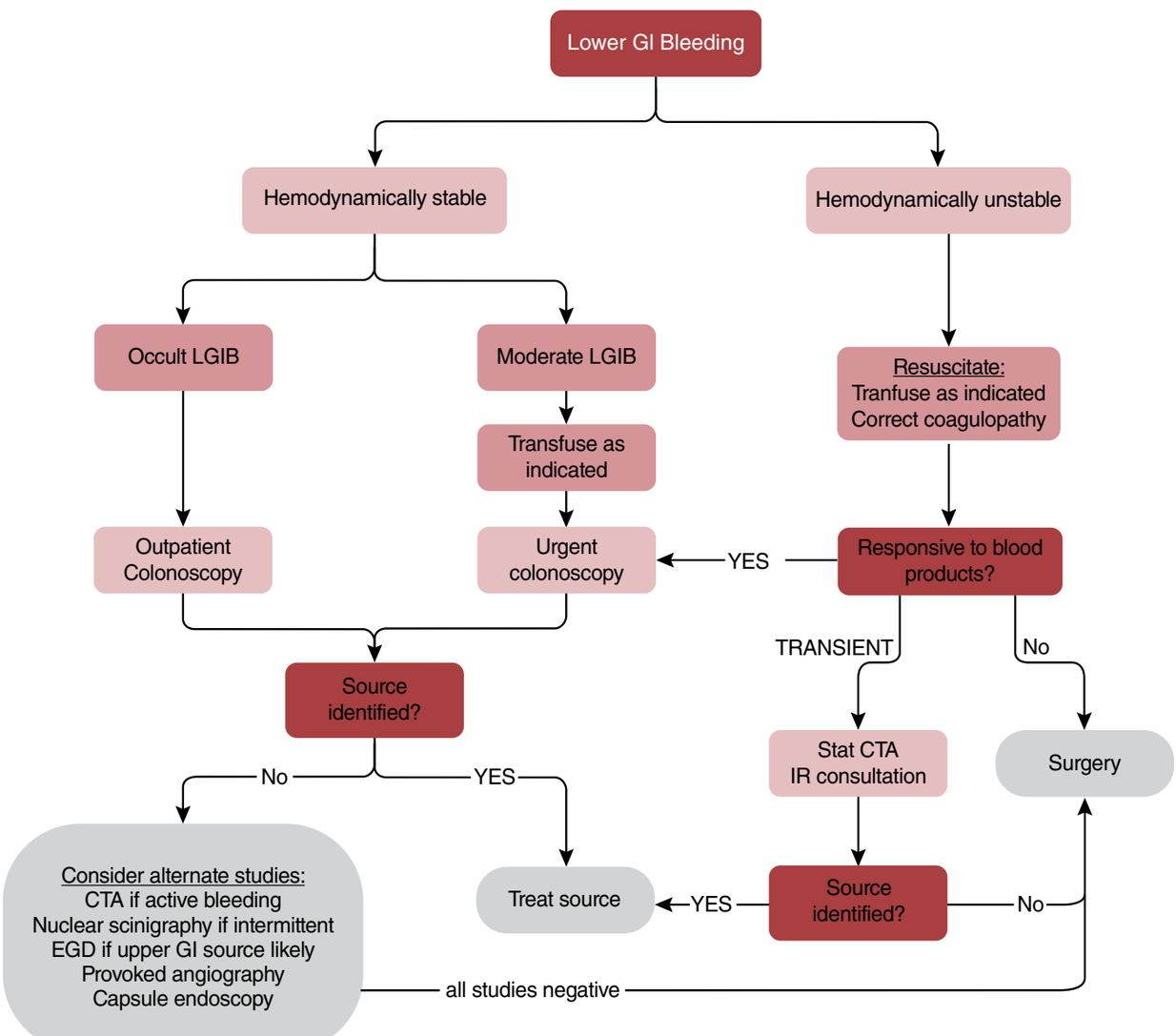

f0380

FIG. 5 Algorithm for the management of lower gastrointestinal bleeding. *CTA,* Computed tomography angiography; *EGD,* endoscopy; *GI,* gastrointestinal; *IR,* interventional radiology *LGIB,* lower gastrointestinal bleeding.

will recur within 6 to 12 months. Other forms of LGIB will also spontaneously resolve at high rates, including angiodysplasias, the most common cause of obscure LGIB. These may also recur at rates nearing 50% within 1 year. Although observation and serial hemoglobin monitoring may be an acceptable monitoring plan in some patients, therapeutic intervention with endoscopic or interventional techniques is preferred by surgeons whenever possible.

p3780 In patients with massive LGIB or moderate LGIB with instability, emergent CTA should be performed if the patient transiently responds to blood transfusion. Early notification of the interventional radiology team for possible angiography with embolization is crucial in the critically ill patient, and CTA can be bypassed altogether if the patient is increasingly unstable with minimal response to blood transfusion. Emergent esophagogastroduodenoscopy (EGD) should be considered if an upper GI source is suspected based on the history and physical examination. Aggressive resuscitation in a critical care setting along with reversal of coagulopathy and appropriate transfusion should be performed concurrently.

p3785 Emergent surgical intervention is a last resort in the management of LGIB because of high mortality rates but can be necessary and life-saving for some patients. Consequently, it is important for surgeons to be involved in the management of these patients early in their treatment as patients can decompensate quickly, leaving only a small window of opportunity for optimization. In general, emergent surgery is reserved for hemodynamically unstable patients or for those who have undergone failed interventions.

st1625

SURGICAL CONSIDERATIONS

st1630

Indications

p3790 Improvements in endoscopic and interventional radiology hemostatic techniques during recent years has resulted in a decreased role for emergent surgical intervention in patients with LGIB. Current indications for emergency surgical management are limited to failure of nonoperative intervention with a confirmed or presumed source and ongoing bleeding or hemodynamic instability, particularly in patients who have received transfusion of more than 6 units of blood products. In a hemodynamically stable patient, nonurgent surgical intervention may also be warranted in select cases, such as malignancy, bleeding hemorrhoids, or Meckel's diverticulum.

st1635

Operative Technique

p3795 Operative planning relies heavily on localization of the bleeding source and stability of the patient. For most patients with a presumed colonic source, surgical options include either a segmental resection or a subtotal colectomy. For patients with bleeding that cannot be controlled endoscopically, one consideration is to have the endoscopist tattoo the segment to facilitate intraoperative identification, which is an otherwise a difficult task.

p3800 Localization of the bleeding lesion before surgery is helpful to prevent excess mortality from a subtotal colectomy. In most studies, the mortality from this procedure approaches 40%, whereas segmental resection carries only a 20% mortality risk. Additionally, localization ensures that rebleeding from an unresected lesion is prevented. In contrast with the mortality risk, subtotal colectomy carries only a 4% risk of rebleeding, whereas segmental resection has a close to 20% risk. These risks and benefits should be considered on an individual basis with the understanding that the primary goal of surgery is to provide immediate control of the bleeding. If there is any question at all about localization, the surgeon should strongly consider performing a subtotal colectomy.

p3805 Patients requiring emergent colectomy for acute LGIB are at high risk for morbidity and mortality, with close to 60% suffering complications such as respiratory or renal failure. The surgeon should have a low threshold to perform a damage-control operation and delay formal closure of the abdomen. This will allow for ongoing resuscitation of the patient and monitoring for ongoing bleeding in a critical care setting. Temporarily packing the abdomen with laparotomy sponges can be considered for coagulopathic patients with diffuse hemorrhage from surgical surfaces to minimize time in the operating room. The patient can be returned to the operating room in 24 to 48 hours for reexploration and formal closure. The decision whether to create an ostomy or reconstruct the GI tract with an anastomosis can be made at that time. Since an anastomotic leak can be catastrophic, the creation of an anastomosis at the time of initial emergent surgery in the setting of coagulopathy and hemodynamic instability should be discouraged.

st1640

CONCLUSIONS

p3810 LGIB is a heterogeneous disease state consisting of a broad differential diagnosis with a range of severity. Owing to this complexity, a thorough history and physical examination is most important to narrow the differential diagnosis and proceed through a thoughtful diagnostic algorithm. Resuscitation, correction of coagulopathy, and blood transfusion are the cornerstones of management of LGIB and are often the only therapeutic maneuvers necessary given that most patients presenting with LGIB will spontaneously resolve. Endoscopic and interventional radiology procedures should be the initial localization and therapeutic modalities for most patients with LGIB depending on the clinical status of the patient. Surgery is reserved for a small subset of patients with continued hemodynamic instability or failure of less-invasive techniques, but it can be life-saving. Surgeons should be actively engaged in the management of patients with LGIB and should be prepared to intervene in the rare circumstance that this becomes necessary.

st1645

SUGGESTED READINGS

bib0163 Gralnek IM, Neeman Z, Strate LL. Acute lower gastrointestinal bleeding. *N Engl J Med*. 2017;376:1054–1063.

bib0164 Jacovides CL, Nadolski G, Allen SR, et al. arteriography for lower gastrointestinal hemorrhage: role of preceding abdominal computed tomographic angiogram in diagnosis and localization. *JAMA Surg*. 2015;150:650–656.

bib0165 Lau JYW, Yu Y, Tang RSY, et al. Timing of endoscopy for acute upper gastrointestinal bleeding. *N Engl J Med*. 2020;382:1299–1308.

bib0166 Oakland K, Chadwick G, East JE, et al. Diagnosis and management of acute lower gastrointestinal bleeding: guidelines from the British Society of Gastroenterology. *Gut*. 2019;68:776–789.

bib0167 Oakland K, Jairath V, Uberoi R, et al. Derivation and validation of a novel risk score for safe discharge after acute lower gastrointestinal bleeding: a modelling study. *Lancet Gastroenterol Hepatol*. 2017;2:635–643.